

- and chronic disease to Legionnaires' disease: a twelve-month prospective study of sporadic cases in Massachusetts. *Ann Intern Med* 1979; 90: 607-610.
16. Anonymous. Legionnaires' disease [Editorial]. *Br Med J* 1979; 2: 81.
17. Taylor AG, Harrison TG, Andrews BE, Sillis M. Serological differentiation of Legionnaires' disease and *Mycoplasma pneumoniae* pneumonia. *Lancet* 1980; 1: 764.
18. Fleurette J, Bornstein N, Aymard M, Bosshard S. Serological differentiation of Legionnaires' disease and *Mycoplasma pneumoniae* and *Chlamydia psittaci* pneumonia. *J Infect* 1981; 3: 88-89.
19. Grayston JT, Kuo C, Wang S, Altman J. A new *Chlamydia psittaci* strain, TWAR, isolated in acute respiratory tract infections. *N Engl J Med* 1986; 315: 161-168.

20. Saikku P, Wang SP, Kleemola M, et al. An epidemic of mild pneumonia due to an unusual strain of *Chlamydia psittaci*. *J Infect Dis* 1985; 151: 832-839.
21. Yung AP, Newton-John HF, Stanley PA. Atypical pneumonia: recognition and treatment. *Med J Aust* 1987; 147: 132-136.
22. Schaeffer W, Drutz DJ, Duncan GW, Koenig MG. The clinical spectrum of endemic psittacosis. *Arch Intern Med* 1967; 119: 433-443.
23. Schaffner W. *Chlamydia psittaci* (psittacosis). In: Mandell GL, Douglas RG, Bennett JE, eds. Principles and practice of infectious diseases. 2nd edn. New York: John Wiley, 1985: 1061-1063. (Received July 15; accepted August 13, 1987)

The accuracy of manual diagnosis for cervical zygapophysial joint pain syndromes

Gwendolen Jull, Nikolai Bogduk and Anthony Marsland

ABSTRACT The ability of a manipulative therapist to diagnose symptomatic cervical zygapophysial joint syndromes accurately was evaluated in a series of 20 patients. In 11 patients the presence, or absence, of a symptomatic joint was established by means of radiologically-controlled diagnostic nerve blocks. These patients were assessed by the manipulative therapist, without knowledge of the medical diagnosis. Another nine patients were first seen by the manipulative therapist whose diagnosis was then evaluated by means of diagnostic blocks. The manipulative therapist identified correctly all 15 patients with proven symptomatic zygapophysial joints, and specified correctly the segmental level of the symptomatic joint. None of the five patients with asymptomatic joints was misdiagnosed as having symptomatic zygapophysial joints. Thus, manual diagnosis by a trained manipulative therapist can be as accurate as can radiologically-controlled diagnostic blocks in the diagnosis of cervical zygapophysial syndromes. However, before generalized claims about the reliability of manual diagnosis can be made, further studies of this nature are required to validate intertherapist reliability and the ability of manual techniques to diagnose other spinal pain syndromes. (Med J Aust 1988; 148: 233-236)

Manipulative therapists contend that, by means of manual examination, they are able to identify symptomatic, abnormal joints in the vertebral column. A variety of techniques for this purpose has been described previously in textbooks of manipulative therapy.¹⁻⁴ However, few of these techniques have been validated formally in a scientific manner. Therefore, the claims of manipulative therapists are controversial and are the subject of disbelief by those who are outside manipulative practice.

Legitimate questions can be raised, such as: Can manipulative therapists actually feel movements in specific vertebral joints?; Are the allegedly palpable abnormalities at all diagnostic, or are they non-specific signs?; and, in more general terms, Is it possible for manipulative therapists to diagnose accurately vertebral disorders by manual examination? To investigate these issues a formal study of manual examination was undertaken.

The first aim of the study was simply to test the ability of a manipulative therapist (G.J.) to make an accurate diagnosis of symptomatic, abnormal joints in the vertebral column, without regard to the techniques that were used. To maintain uniformity in diagnosis, a particular group of patients was chosen — patients who complained of neck pain or neck pain and headache. Moreover, the study focused on a particular diagnosis, that of neck pain or headache due to cervical zygapophysial joint dysfunction. Radiologically-controlled, diagnostic nerve blocks were used to establish or exclude this diagnosis, and the accuracy of the manipulative therapist's diagnosis was determined by comparison of her diagnosis with the diagnosis that was made "medically" on the basis of these blocks.

The manipulative therapist was required to determine whether or not a symptomatic zygapophysial joint was present, and at what

vertebral level it was present. Either of two results were possible. If accurate, the manipulative therapist would be able to make the diagnosis correctly in virtually all cases. Inaccuracy of manual diagnosis would be revealed if the manipulative therapist failed to detect the presence of a symptomatic joint, or claimed that joints were symptomatic when, in fact, they were not.

A subsidiary issue that was addressed in this study was whether the manipulative therapist could, in fact, palpate individual vertebral segments. If the manipulative therapist could not identify specific vertebral joints, she would fail to make an accurate diagnosis consistently. However, conversely, a consistently-accurate diagnosis would imply the capacity of the manipulative therapist to feel selectively individual vertebral joints.

Patients and methods

Patients

The patients were consecutive patients who presented with cervical pain to the Pain Clinic at the Princess Alexandra Hospital between January 28, 1982 and October 24, 1984. All such patients who were seen at the clinic during the period of study consented to participate in the study. None was excluded. It had been intended to exclude patients with objective neurological signs of radiculopathy, but no such patients presented during the period of study.

There were seven men and 13 women. Fourteen patients complained of neck pain and headache; three patients complained of neck and arm pain; and three patients complained of neck pain alone. All patients had had chronic pain for at least 12 months.

To enable a crossover study design, the patients were divided into two groups that were studied sequentially. Group I comprised 11 patients who were first evaluated by means of diagnostic nerve blocks, and were then referred, on a single-blind basis, for examination by a manipulative therapist. Diagnostic blocks established the presence and location of a symptomatic zygapophysial joint in eight of these patients and excluded symptomatic zygapophysial joints in the other three patients. These latter three patients were, none the less, referred for manual examination to serve as control patients. All patients were examined by the manipulative therapist between one and four weeks after the initial diagnostic block procedure, at which time the effects of the block had worn off and no trace of any needle-puncture site remained. This was to preclude the manipulative therapist from allowing the puncture site to act as an overt or subconscious clue as to the diagnosed level of the symptomatic joint.

Group II comprised nine patients with unknown diagnoses who were first examined by the manipulative therapist, who specified whether or not a symptomatic joint was present and, if present, at which level. Subsequently, her diagnosis was evaluated by means of diagnostic blocks.

Diagnostic blocks

Two forms of diagnostic nerve blocks were used — cervical medial-branch blocks and direct intra-articular blocks. Cervical medial-branch blocks were used in all patients as this long-established procedure was in routine use in our Pain Clinic. Our capacity to perform direct intra-articular blocks was developed only more recently, and was introduced late in the study for the final six patients.

Cervical zygapophysial joints are innervated by the medial branches of the cervical dorsal rami; thus, the principle of cervical medial-branch blocking is that blocks of the appropriate medial branches will relieve the pain that stems from a particular joint. The target points for cervical medial-branch blocks were the waists of the articular pillars (Figure 1).⁵ At the C3 level, blocks of the third occipital nerve were performed at the lateral margin of the C2-3 zygapophysial joint.^{5,6}

University of Queensland, St Lucia, QLD 4067.

Gwendolen Jull, MPTy, GradDipManTher, MAPA, MMTAA, FACP, Senior Lecturer, Department of Physiotherapy.

Nikolai Bogduk, BSc(Med), MB BS, PhD, DipAnat, Hon MMTAA, formerly Reader, Department of Anatomy and Visiting Medical Officer, Pain Clinic. Currently, Senior Lecturer, Faculty of Medicine, The University of Newcastle.

Pain Clinic, Princess Alexandra Hospital, Ipswich Road, Woolloongabba, QLD 4102. Anthony Marsland, MB ChB, FFRACCS, Clinical Lecturer and Visiting Medical Officer.

Reprints: Miss G. Jull.

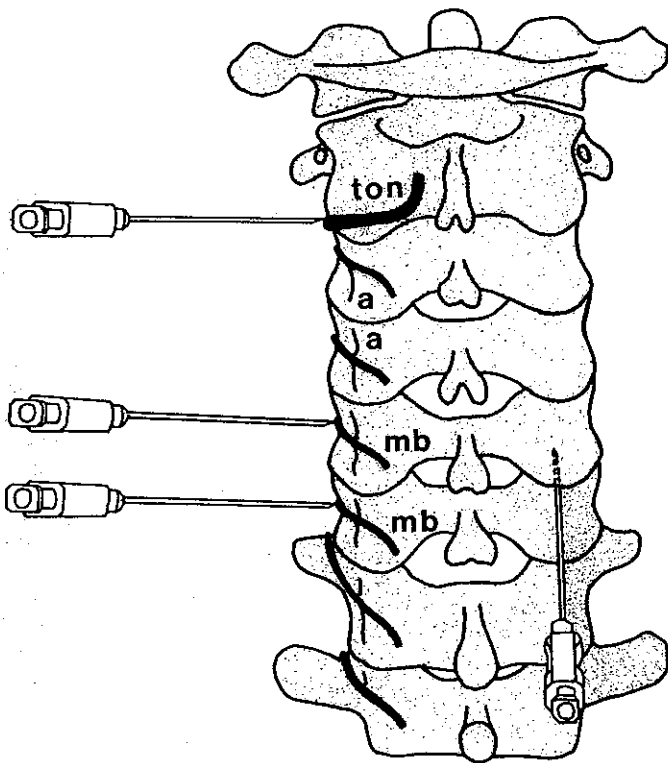


FIGURE 1: Posterior view of the cervical spine showing the location of the third occipital nerve (ton), the medial branches of the cervical dorsal rami (mb) and their articular branches (a) to the zygapophysial joints. On the left, needles have been introduced onto the target points that are used for blocks of the third occipital nerve, and the C5 and C6 medial branches. On the right, the insertion of a needle into the C5-6 joint is illustrated.

Blocks were performed under fluoroscopic control by means of a 22-gauge (0.70-mm) spinal needle that was introduced along a posterolateral approach to the particular target point. Each target nerve was infiltrated with no more than 1.5 mL of 0.5% bupivacaine.

To establish a diagnosis, each patient underwent a systematic series of blocks. The point of maximum tenderness over the zygapophysial joints was identified in each patient, and blocks were undertaken of the nerves to the joint that was presumed to underlie this point. If these blocks failed to relieve all symptoms of pain and pain-provoking movement, blocks were then undertaken at levels above or below the first site, until a symptomatic level was determined, or until no blocks could be shown to relieve the patient's symptoms. A positive result of a block was defined as complete relief of symptoms for at least three hours — the expected duration of action of bupivacaine.

Since the manipulative therapist was to make a diagnosis in terms of vertebral segments, the results of the diagnostic nerve blocks had to be translated from neurological terms to the identification of a putatively-abnormal joint. To do this the following guide-lines were adopted. Because the C2-3 zygapophysial joint is supplied by the third occipital nerve,⁵ positive results of blocks of this nerve were interpreted as diagnostic of C2-3 zygapophysial arthropathy.⁶ Below the C3 joint, each cervical medial branch supplies two consecutive zygapophysial joints, and conversely each joint receives a dual innervation.⁵

Therefore, blocks at two consecutive levels are required to anaesthetize completely a given joint. However, dual blocks also anaesthetize partially the joints above and below the fully anaesthetized joint, which results in a potential ambiguity in the inferred diagnosis. The interpretation that we used was that if dual-level blocks relieved the symptoms completely, the symptomatic joint was then most likely to be the one that was bracketed by the blocks and anaesthetized fully. It was unlikely that the joints above and below the fully anaesthetized joint were the symptomatic ones as their unanaesthetized nerves would still be able to give rise to symptoms.

As an example, the C5 and C6 medial branches together innervate the C4-5, C5-6 and C6-7 zygapophysial joints.⁵ Therefore, blocks of the C5 and C6 medial branches anaesthetize the C5-6 joint fully and anaesthetize the C4-5 and C6-7 joints partially. Since C5-6 is the only joint that is anaesthetized fully, positive results of blocks of the C5 and C6 medial branches were inter-

preted as diagnostic of C5-6 arthropathy. When symptoms arose from two consecutive joints, three nerves had to be blocked to relieve symptoms. Thus, positive results of blocks of the C3, C4 and C5 medial branches indicated symptomatic joints at C3-4 and C4-5. These interpretations were validated by the use of corroborating intra-articular blocks in the last six patients in the study.

Intra-articular blocks were performed under fluoroscopic control by means of a 22-gauge (0.70-mm) spinal needle. The needle was inserted posteriorly, two segments below the target joint and advanced rostrally and ventrally towards the posterior margin of the joint (Figure 2). It was then introduced into the joint cavity, its course being checked repeatedly by posteroanterior and lateral screening on an image-intensifier. Once its tip was gauged to be within the centre of the joint, as seen on posteroanterior and lateral views on the image-intensifier, 1 mL of 1% lignocaine was injected into the cavity. A positive response was considered to be complete relief of all symptoms for at least one hour — the expected duration of action of lignocaine.

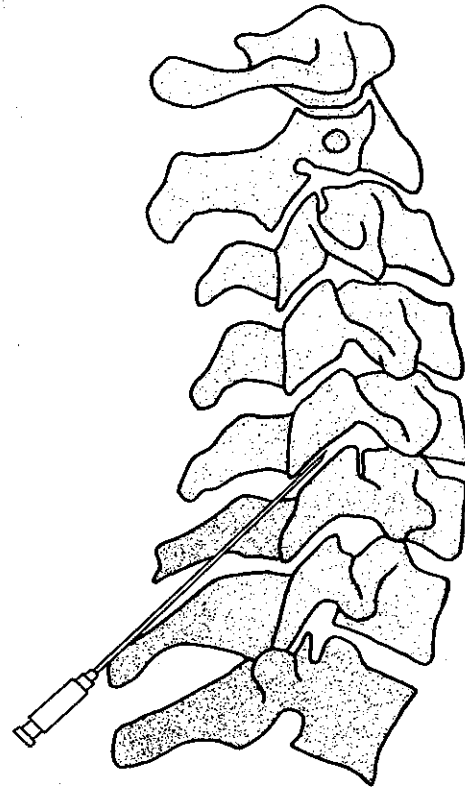


FIGURE 2: Right lateral view of the cervical spine showing the penetration of a needle introduced into the C5-6 zygapophysial joint cavity.

Manual examination

The manipulative therapist's examination involved the manual testing of the mechanical properties of all the cervical joints. Abnormalities were sought in the perceived stiffness properties of individual joints, that is, the relationship between perceived passive displacement of the joint and its resistance to displacement. Decisions on joint abnormality were based on the findings of a documented, previous study of 90 subjects in which the physical properties of cervical joints were assessed manually in an asymptomatic population of a wide age range.⁷

The manual examination was performed in the context of a full subjective and objective examination, and it was intended that the manual examination would include the assessment of both passive accessory and passive physiological intervertebral movements of all cervical segments.³ However, in the course of the study it was found that this intention had to be compromised in deference to the high "irritability" of the pain in many subjects. Many of the patients could not tolerate a full examination of every joint movement. Therefore, it was decided to assess, at the minimum, the passive, accessory intervertebral movements in all subjects.³

The passive accessory movements that were examined were the postero-anterior glides, which were performed centrally over the spinous processes, and unilaterally those of the laminae and zygapophysial joints of all segmental levels that were putatively relevant to the patient's complaint. Where

possible, the extension, the

Because zygapophysial joints "end-feel" of motion); pain, either To be diagn of these crit other abno ones.

TABLE 1: C

Patient
1
2
3
4
5
6
7
8
9
10
11

t = left, R = right

TABLE 2: C

Patient
1
2
3
4
5
6
7
8
9

t = left, R = right

Results

The result with a kn were iden presence c correctly. zygapophys therapist

The rest therapist c the sympt- symptoms (C1-2), w neck. Dis Moreover the manip from the 1 no signs of occipital n infiltration nerve just

The sen zygapophy of manual of diagnos

ose from two
ptoms. Thus,
hes indicated
ere validated
six patients in

ontrol by means
d posteriorly,
and ventrally
en introduced
steroanterior
gauged to be
lateral views
to the cavity.
all symptoms
lignocaine.

possible, the passive physiological intervertebral movements of flexion, extension, lateral flexion and rotation were also examined.

Because movement abnormalities are palpable even in asymptomatic zygapophysial joints,⁷ criteria had to be determined by which the symptomatic joints could be identified. The criteria that were adopted were: abnormal "end-feel" (that is, an abnormal quality of resistance at the extreme range of motion); abnormal quality of resistance to motion; and reproduction of pain, either local or referred, when passive accessory movements were tested. To be diagnosed as the symptomatic joint, a joint had to exhibit all three of these criteria. Other joints that did not satisfy all three criteria, or with other abnormalities, were recorded but not deemed to be the symptomatic ones.

TABLE 1: Concordance between medical diagnosis and manual diagnosis of symptomatic cervical zygapophysial joints

Patient	Medical diagnosis		Manual diagnosis
	Nerve block	Likely joint	Symptomatic joint
1	L C3	L C2-3	L C2-3
2	L C3	L C2-3	L C2-3
3	L C3	L C2-3	L C2-3
4	R C3	R C2-3	R C2-3
5	R C3	R C2-3	R C2-3
6	R C3	R C2-3	R C2-3
7	R C5, C6	R C5-6	R C5-6
	R C6, C7	R C6-7	
8	R C5, C6	R C5-6	R C5-6
9	Negative results	Not zygapophysial	Not zygapophysial
10	Negative results	Not zygapophysial	Not zygapophysial
11	Negative results	Not zygapophysial	Not zygapophysial

L = left, R = right.

TABLE 2: Concordance between manual diagnosis and medical diagnosis of symptomatic cervical zygapophysial joints

Patient	Manual diagnosis	Medical diagnosis		
	Symptomatic joint	Nerve block	Likely joint	Joint block
1	R C2-3	R C3	R C2-3	
2	R C3-4	R C3, C4	R C3-4	
	R C4-5	R C4, C5	R C4-5	
3	R C2-3	R C3	R C2-3	R C2-3
4	L C2-3	L C3	L C2-3	L C2-3
5	R C3-4	R C3, C4	R C3-4	R C3-4
6	L C3-4	L C3, C4	L C3-4	L C3-4
7	R C5-6	R C5, C6	R C5-6	R C5-6
8	R C1-2			R C1-2
9	Zygapophysial joints normal	Blocks revealed a greater occipital nerve neuroma		

L = left, R = right.

Results

The results for Group I are shown in Table 1. Of the eight patients with a known symptomatic zygapophysial joint, all abnormalities were identified correctly by the manipulative therapist. Both the presence of a symptomatic joint and its location were determined correctly. The three patients who did not have a symptomatic zygapophysial joint were also identified correctly by the manipulative therapist who thereby offered no false-positive diagnoses.

The results for Group II are shown in Table 2. The manipulative therapist determined that a zygapophysial joint was responsible for the symptoms in seven of these patients; and that one patient had symptoms that were referable to the right lateral atlantoaxial joint (C1-2), while one patient had no abnormalities in the joints of the neck. Diagnostic nerve blocks corroborated these diagnoses. Moreover, in six patients intra-articular blocks corroborated both the manipulative therapist's diagnoses and those that were derived from the results of nerve blocks. The patient in whom there were no signs of joint abnormality was found to have an iatrogenic greater occipital nerve neuroma, which was diagnosed by the subcutaneous infiltration of a local anaesthetic agent into the right greater occipital nerve just below the superior nuchal line.

The sensitivity of the manual diagnosis of symptomatic cervical zygapophysial joints (that is, the number of correct positive results of manual diagnosis divided by the total number of positive results of diagnostic blocks, or 15 divided by 15) was 100%. The specificity

(the number of correct positive results of manual diagnosis divided by the total number of positive results of manual diagnosis: 15 divided by 15) was also 100%.

Discussion

The reliability of cervical medial-branch blocks might, in principle, be questioned for *prima facie* they do not anaesthetize a particular zygapophysial joint specifically. However, medial-branch blocks were used in this study because as a screening procedure: they are easier to perform than are intra-articular blocks; they are less traumatic (they require the penetration only of muscle, instead of joint capsules); they are less hazardous (for the injection is made on the surface of the vertebral column, not near the vertebral canal and spinal cord as is the case with intra-articular blocks); they require less radiographic screening than do joint blocks; and they are better tolerated by patients than are intra-articular blocks. Moreover, it is arguable that medial-branch blocks are at least as specific as are direct intra-articular blocks.

Each cervical medial branch has a discrete distribution to zygapophysial joints, to an interspinous muscle, and to specific bands of the multifidus muscle.⁵ Therefore, a positive result of a medial-branch block implies a source of pain only within one or more of these tissues. Interspinous-muscle diseases are unknown in the cervical region, and are unlikely to be the source of pain in patients without discrete midline tenderness, as was the case in our patients. Although spasm and strain of the posterior neck muscles is regarded as a possible cause of neck pain, it seems highly unlikely for such abnormalities to affect just the particular myotome that is anaesthetized by a medial-branch block.

Therefore, by deduction, the zygapophysial joints are the only likely source of persistent pain that can be relieved by cervical medial-branch blocks. Indeed, this conclusion is vindicated by the results of the corroborating joint blocks that were performed in the patients in Group II. The results of these blocks also vindicate the guidelines that were used in this study to translate the results of nerve blocks into the identification of the joint that was most likely to be the source of symptoms.

One plausible hypothesis is that certain neck-pain syndromes could be due to a combination of articular and muscular abnormalities. However, this possibility does not detract from the accuracy of our study. Anatomical studies have shown that, in the neck, those fascicles of the multifidus muscle that move a particular vertebra are supplied by the same medial branch that issues from below that vertebra and innervates its lower joints.⁵ Thus, the C5-6 joint and all the fibres of the multifidus muscle that act on C5 are innervated by the C6 medial branch.

Consequently, if it were suggested that a patient's symptoms and signs were due to muscular restriction of a segment, rather than or in addition to an articular restriction, our segmental diagnoses are accurate none the less. Restriction of C5 due to disease of the C5-6 joint or to spasm of the muscles that act on C5 would, in either case, be relieved by C6 blocks. Thus, while our blocks might not discriminate between muscular and articular abnormalities they do indicate accurately the segment at which a manipulative therapist would detect abnormalities. Therefore, they are an adequate control test by which to assess a manipulative therapist's accuracy.

With respect to the issues that are addressed by this study, it was found that the manipulative therapist who was tested was remarkably accurate. In Group I, all patients with symptomatic zygapophysial joints were diagnosed correctly and discriminated correctly from those patients without symptomatic joints. Moreover, the segmental locations of all symptomatic joints were identified correctly.

Because the manipulative therapist was aware that the Pain Clinic had a particular interest in zygapophysial joint syndromes, it could be argued that she could justifiably expect consistent referrals of patients with this condition, which would allay much of the challenge to her diagnostic capacity. It was to counter this possible bias that the study of Group-II patients was undertaken.

netration of s

testing of the
were sought
e relationship
resistance to
e findings of
al properties
opulation of

all subjective
examination
ssive physio-
wever, in the
ompromised
jects. Many
it movement
re, accessory

the posterio-
is processes
all segmental
aint. Where

Although they were interviewed, and a history was taken, none of the patients in Group II was investigated before being seen by the manipulative therapist. Consequently, neither the medical team nor the manipulative therapist had any knowledge of the cause of the patients' symptoms. This eliminated any bias towards zygapophysial syndromes on the part of the medical team, for essentially the patients could be suffering cervical pain due to any cause. Even under these conditions, the manipulative therapist's diagnosis was validated in all cases.

It might be remarked that in spite of the lack of preselection of the patients in Group II, there was an inordinate prevalence of patients with zygapophysial syndromes in this group. We reiterate that this does not reflect any preselection of patients on our part. As far as the manipulative therapist was concerned the patients in Group II could have presented with any cause of cervical pain. The inordinate prevalence of zygapophysial syndromes in the present study reflects the catchment of our Pain Clinic and underscores the unrecognized prevalence of these syndromes in conventional practices. This issue is explored in further detail elsewhere.⁸

Groups I and II differed in the relative prevalence of joint disorders at the C2-3 level. Of the patients with positive responses in Group I, virtually all had C2-3 symptoms. Again, this was not due to any preselection, and reflects the apparently inordinate prevalence of these syndromes in our Pain Clinic.

The foremost issue that was addressed by the present study was the accuracy of manual diagnosis, and the results that we obtained vindicate the claims of manipulative therapists. On the basis of our results we can conclude that for the diagnosis of symptomatic cervical zygapophysial joints, manual examination by a trained manipulative therapist is as accurate as are radiologically-controlled diagnostic blocks.

As a result of this positive finding the subsidiary issue that was addressed by this study — the capacity to feel specific vertebral segments — is also resolved in the affirmative. The manipulative therapist could not possibly have made accurate diagnoses so consistently had she not been able to palpate and assess specific vertebral segments.

While vindicating the claimed diagnostic capacity of a manipulative therapist in a qualitative sense, the results of the present study also permit a quantification of her diagnostic capacity. Any diagnostic test can be quantified in terms of its sensitivity and specificity. Sensitivity is a measure of how frequently a test detects a condition when that condition is definitely known to be present. A good test has a sensitivity of near to 100% (that is, it fails to detect few cases with the sought-for condition). Specificity is a measure of how often a test-result is positive because of other conditions that may mimic a sought-for condition. A good test has a specificity of near to 100% (that is, it has few false-positive results).

In this context, the present results show that the techniques that were used by the manipulative therapist who was tested had both a sensitivity and specificity of 100%. The pooled results of Groups I and II show that 15 patients definitely had zygapophysial pain syndromes, and all 15 patients were detected correctly by manual examination. Reciprocally, five patients did not have zygapophysial pain syndromes, and these were identified correctly also. The manipulative therapist did not offer any false-positive or false-negative diagnoses. The techniques that she used were highly specific for symptomatic zygapophysial joints.

This high accuracy vindicates the criteria that were chosen by the manipulative therapist for making her diagnosis. Therefore, it may be concluded that the joint signs that are pathognomonic of symptomatic cervical zygapophysial joints are: abnormal "end-feel", abnormal quality of resistance to motion, and reproduction of pain.

There were no theoretical reasons for choosing these criteria at the outset of the study, and their choice might be regarded simply as fortuitous, for there was every prospect that they might not have been vindicated. However, this was not the case. A more benevolent interpretation is that they were chosen intuitively by the manipulative

therapist on the basis of many years' experience in manual therapy. Regardless of the reason for their choice, the criteria were proved to be valid.

While the definitions of the criteria that were used in the present study may be familiar to *aficionados* of manipulative therapy, they are likely to be unfamiliar to others. They are described in full detail elsewhere,³ but some explanation may be appropriate here. Reproduction of pain is self evident, but "abnormal end-feel" and "abnormal quality of resistance" may seem to be esoteric terms. We make no claim as to the actual physical basis for these perceptions, but by way of example we offer several putative explanations.

In the first instance, "abnormal end-feel" is defined as a difference from that expected and experienced in normal joints. The capacity to discriminate this difference depends on extensive training and experience. Translated into pathological terms, "abnormal end-feel" would be the sensation that one would expect when the range of motion of a joint is restricted by capsular contracture or the onset of unyielding muscle spasm. The physical characteristics of such states would be different from those of a normal joint whose motion was limited by a normal capsule.

"Abnormal quality of resistance" refers to the palpatory equivalent of a stress-strain curve of a joint. Normally, a joint permits passive movement in response to a minimal force. However, an abnormal quality of resistance means that a greater than normal force has to be applied to achieve the same degree of movement. Pathologically, this could occur in the presence of: muscular spasm that braces the joint, an increase in joint viscosity as might occur after proliferation of fat within the joint, the development of intra-articular adhesions, or the loss of synovial fluid and erosion of articular cartilage.

While it is acknowledged that there may be other criteria that are pathognomonic of symptomatic zygapophysial joints, it is emphasized that the triad that is described above is the only set of criteria that, to date, has been evaluated formally and corroborated. Thus, while other diagnostic criteria may continue to be proclaimed they still remain to be proved. We also emphasize that simple joint stiffness is not pathognomonic of a symptomatic cervical zygapophysial joint, for, as reported elsewhere, such stiffness occurs frequently in asymptomatic individuals.⁷ Symptomatic joints must exhibit some additional abnormality.

Also, we emphasize that our study does not vindicate manual diagnosis in general. First, only one particular condition was studied, and only one particular manipulative therapist was evaluated. For more widespread vindication of manual diagnosis, further studies will have to establish intertherapist reliability, and the accuracy of manual diagnosis for other vertebral conditions, such as lumbar zygapophysial joint syndromes, and cervical and lumbar disc syndromes. Nevertheless, the results of the present study augur favourably, and there is every prospect that appropriate studies will further vindicate the claims of manipulative therapists, or at least provide a measure of their actual accuracy.

Acknowledgements

This paper received the Wagemacker Award of the Fédération Internationale de Manuelle Médecine, 1986, for research into manual medicine.

References

1. Bourdillon JF. Spinal manipulation. 3rd edn. London: Heinemann, 1982.
2. Grieve GP. Common vertebral joint problems. Edinburgh: Churchill Livingstone, 1981.
3. Maitland GD. Vertebral manipulation. 4th edn. London: Butterworths, 1977.
4. Stoddard A. Manual of osteopathic technique. London: Hutchinson, 1983.
5. Bogduk N. The clinical anatomy of the cervical dorsal rami. *Spine* 1982; 7: 319-330.
6. Bogduk N, Marsland A. On the concept of third occipital headache. *J Neurol Neurosurg Psychiatry* 1986; 49: 775-780.
7. Jull GA. Clinical observations of upper cervical mobility. In: Grieve GP, ed. Modern manual therapy of the vertebral column. Edinburgh: Churchill Livingstone, 1987: 315-321.
8. Bogduk N, Marsland A. The cervical zygapophysial joints as a source of neck pain. *Spine* 1988 (in press).

(Received February 27; accepted August 19, 1987)

ME

Con
Part

M

approve
credit o
directed
continui
by the f
unwelco
occurrec
lated the
relicens
continui
cation w
There

NSW Facul
St Leonard
Jeanette Wa
Reprints: D

The ar

The c
prog
The p
appe
Fundii
parti
speci
Contin
the r
quali
It imp
There

The arj

The acc
only
Compu
learn
that tl
of enl
The pot
lation
not be
The ess
person
ignore
The pol
As a leg
of civi
The acc
is, a m
Such a s
tional
creatio
May red
time a